

Evaluation of Weakness

Part 1: Upper motor neuron weakness

Samantha LoRusso, MD

Assistant Professor-Clinical

Department of Neurology

The Ohio State University Wexner Medical Center

Localization

- Central Nervous System

- Brain
- Spinal cord



*Upper motor
neuron signs*

- Peripheral Nervous System

- Cranial nerves
- Spinal nerves and dorsal root ganglia
- Motor neuron
- Plexus
- Peripheral Nerves
- Muscle
- Neuromuscular junction



*Lower motor
neuron signs*

Sign/Symptom	Upper Motor Neuron Lesion	Lower Motor Neuron Lesion
Atrophy	No	Yes
Fasciculations	No	Yes
Reflexes	Increased Clonus	Decreased
Plantar Response	Upgoing	Downgoing
Tone	Increased	Decreased
Pain	Less common	More common
Facial weakness	Sparing of forehead wrinkle and able to fully close eyes	Unable to wrinkle forehead, unable to close eyes fully
Pronator drift	Can be present	Not present

Clues to Central Nervous System Localization

Brain

- Weakness on one side of the body
- Facial weakness
- Other symptoms such as dysarthria, dysphagia, aphasia, visual symptoms, ataxia, headache, memory problems

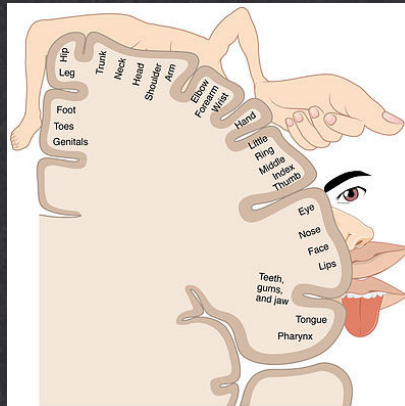
Spinal cord

- Bilateral weakness
- Presence of a 'sensory level'
- Bowel or bladder symptoms

Exceptions to the rules

Brain lesions that cause bilateral weakness

- Multiple lesions on both sides of the brain
- Bilateral watershed infarcts, bilateral brainstem lesions, bilateral medial frontal lesions
- Also note that **'crossed' findings** (symptoms on one side of the face and on the opposite side of the body) are classic for a **brainstem lesion**

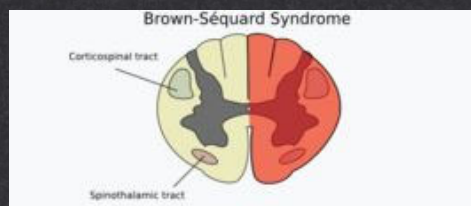


OpenStax College (CC BY 3.0)

Exceptions to the Rule

Spinal cord lesions that cause unilateral weakness or facial symptoms

- Any lesion only affecting one half of the spinal cord
 - Often presents as a Brown-Sequard syndrome: weakness and reduced vibration and proprioception ipsilateral to the lesion and reduced pinprick sensation contralateral to the lesion.
- High cervical lesions may involve the spinal trigeminal nucleus and can cause decreased facial sensation but NOT weakness.



Niels Olson (CC BY-SA 3.0)

Case Presentation 1

64 year old man who says that 2 weeks ago he was sitting, drinking a beer and watching TV and noticed that his right arm felt weak. He then went to bed and by the next morning was unable to move his hand at all so he went to the emergency room. In the emergency room, he reports that they performed a CT of the brain which was unremarkable so he was sent home. Since then it has gotten a little better– now he is able to grip a little bit. Denies numbness and pain. Denies other symptoms.

Examination

- Mental Status: normal.
- Cranial nerves: normal.
- Motor exam: 5/5 strength throughout except for **4+/5 strength in his proximal right arm and 2/5 strength in his right hand. There is right pronator drift.** Bulk and tone are normal.
- Reflexes: **2+ in the right biceps**, otherwise 1+ on the right and left arms. 0 in the knees and ankles.
- Sensation: Symmetric to pinprick. Decrease in vibration in the toes.
- Coordination: normal
- Gait: normal

Work-up

- MRI Brain without contrast: **a small acute ischemic cortical infarct is noted in the left precentral gyrus.**
- Followed by a stroke work-up and management of risk factors.

Clues to Stroke Diagnosis

- History: sudden onset of symptoms, painless, PMHx
- Exam: Relatively increased reflexes in the area of weakness, pronator drift and the fact that the weakness does not follow a clear nerve root or nerve distribution suggests an upper motor neuron process.
- Upper motor neuron findings on exam with weakness on only one side of the body suggests the Brain

Why was the CT of the brain negative?

- The stroke was small
- The CT scan was done soon after symptom onset– strokes become more clear on CT 6-12 hours after symptom onset
- Also note that the CT does a very poor job of imaging the brainstem (not relevant in this case)

Case Presentation 2

52 year old man who woke up one day around June 2016 and noticed that he had a difficult time walking, specifically because of right leg weakness. He also noted some right foot numbness around November 2018. He thinks that his problem has been slowly getting worse over time. He said that he will trip and has to drag his right leg. He also has to drive with two feet because he can't move his right leg from one pedal to the other. Denies bowel/bladder problems. No pain.

Examination

- Mental status and Cranial nerves normal
- Motor: 5/5 strength in both upper extremities and in the left lower extremity. In the right lower extremity he had **2/5 hip flexion, 4/5 knee extension, 2/5 knee flexion, 4/5 dorsiflexion and 4+/5 plantar flexion.**
- Reflexes:

	Right	Left
Biceps	3	2
Triceps	1	1
Brachioradialis	2	1
Patella	3	2
Achilles	2	1
Plantar response	Upgoing	Mute

Examination

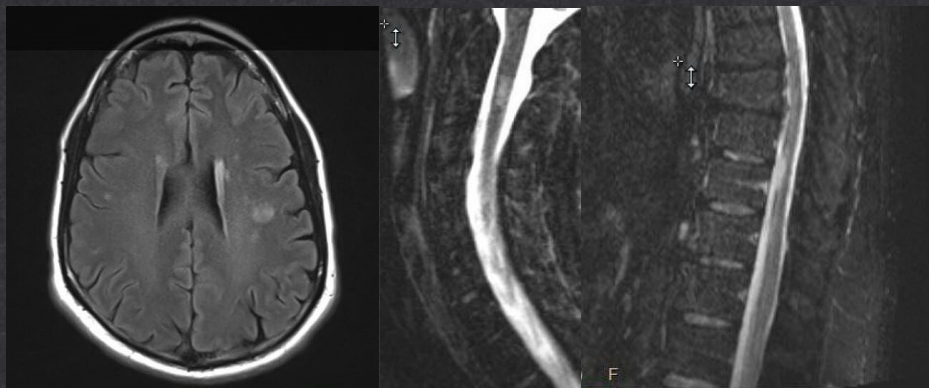
- Sensory: **Decreased in the right leg to pinprick and vibration compared to the left otherwise normal.**
- Coordination: normal
- Gait: **hemiplegic in the right lower extremity**
 - **View Video Demonstration from link on webcast downloads for this webcast.**

Previous testing done prior to referral

- MRI Hip: mild bilateral hip joint osteoarthritis
- EMG/NCS: Normal
- MRI Lumbar spine without contrast: mild disc bulging diffusely. Mild to moderate foraminal narrowing throughout.
- CT of the brain unremarkable

Diagnostic work-up

- MRI of the brain, cervical and thoracic spinal cord with and without contrast



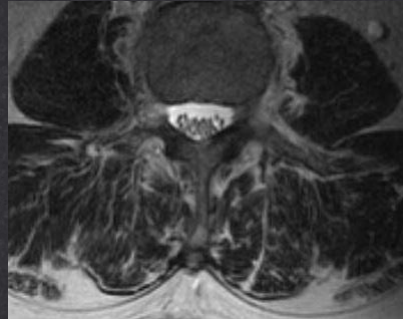
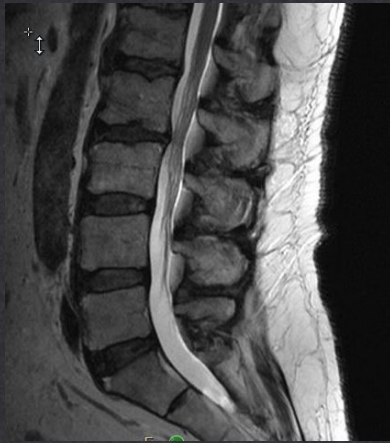- **Diagnosis: Primary progressive multiple sclerosis**

Clues to localization

- **Clear upper motor neuron signs and painless**
 - **Would not necessarily expect EMG/NCS or MRI of the lumbar spine to be abnormal**

Why would you not expect MRI of the lumbar spine to be abnormal?

- MRI of the lumbar spine only images the bottom of the spinal cord and the cauda equina



Case Presentation 3

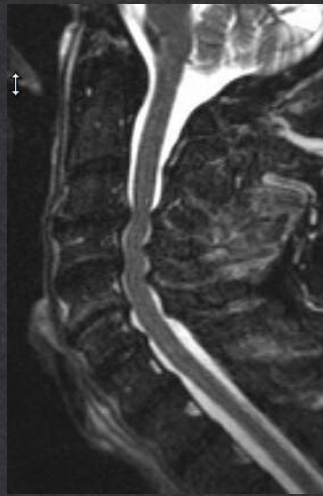
71 year old man presents with 2 years of worsening gait problems. He reports that his legs felt “wobbly” as if they were going to buckle while walking. When asked about numbness or tingling, he said that he had noticed some numbness in his hands over the same time period. Denied any other symptoms.

Examination

- Mental Status: normal
- Cranial nerves: normal
- Motor exam: Normal with the exception of **4+/5 hip flexor weakness bilaterally. Tone mildly increased in the legs.**
- Reflexes: **3+ throughout with bilateral upgoing toes**
- Sensation: **decreased vibratory and pinprick sensation in his hands and feet** without a clear sensory level
- Coordination: normal
- Gait: normal

Work-up

- MRI Cervical and thoracic spine without contrast
- Other myelopathy labs such as vitamin B12, Copper, Vitamin E



Clues to localization and diagnosis

- ***Bilateral weakness with upper motor neuron signs so most likely spinal cord localization***
- **A thoracic lesion may be suggested by the lack of arm weakness BUT**
 - **The patient had sensory changes in his hands that would not be explained by a thoracic lesion**
 - **Cervical spondylotic myelopathy is more common! It is the most common cause of spinal cord dysfunction worldwide in patients older than 55 years old.(Nouri et al., 2015)**
 - **It is common for cervical lesions like this to cause more symptoms in the lower extremities than in the upper extremities (Stino et al., 2018)**

Imaging in structural spine disease

- **MRIs are superior to x-rays and CT scans for imaging of the spinal cord and the nerve roots.**
- **If a patient cannot get an MRI, but structural spine disease is suspected then a CT myelogram should be performed.**
- **If significant structural spinal cord abnormalities are found then the patient should be referred to a neurosurgeon**

Don't forget

- Localize—does the patient have an 'upper motor neuron' exam?
- Bilateral lower extremity weakness with clear upper motor neuron signs should prompt evaluation of the spinal cord
- Unilateral weakness should prompt imaging of the brain
- Almost always appropriate to refer to neurology when weakness and upper motor neuron findings on exam, but would always start with imaging of the CNS
- If there is a compressive lesion then referral to neurosurgery

References

- Blumenfeld H. Neuroanatomy through clinical cases. 2002.
- https://en.wikipedia.org/wiki/Cortical_homunculus
- https://en.wikipedia.org/wiki/Brown-S%C3%A9quard_syndrome
- Nouri A, Tetreault L, Singh A, et al. Degenerative cervical myelopathy: epidemiology, genetics, and pathogenesis. Spine 2015;40(12):E675-E693.
- Stino AM & LoRusso SJ. Myelopathies due to structural cervical and thoracic disease. Continuum 2018 Apr;24(2, Spinal Cord Disorders): 567-583.

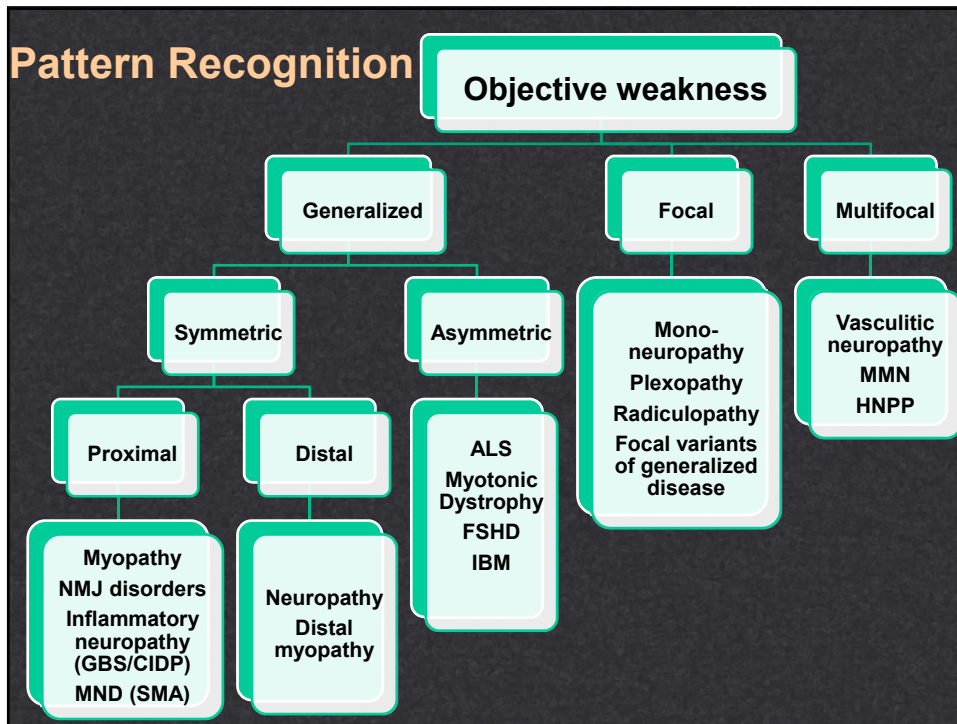
Evaluation of Weakness

Part 2: Lower motor neuron weakness

Bakri Elsheikh, MBBS, FRCP, FAAN
Associate Professor-Clinical
Director of the EMG Laboratory
Department of Neurology
The Ohio State University Wexner Medical Center

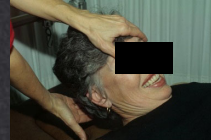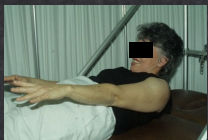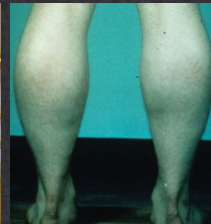Localization! *Lower motor neuron*

- Peripheral Nervous System
 - Cranial nerves
 - Spinal nerves and dorsal root ganglia
 - Motor neuron
 - Plexus
 - Peripheral Nerves
 - Muscle
 - Neuromuscular junction



Symmetric Proximal Predominant Weakness Pattern

- Sensory examination –normal
 - Myopathy
 - NMJ Disorder
 - MND- SMA
- Sensory examination –abnormal
 - GBS
 - CIDP
- Remember to examine muscles against gravity
 - Hip abductors
 - Axial muscles
- Clues
 - Cranial (ocular, facial, pharyngeal)
 - Calf hypertrophy
 - Scapular winging
 - Scoliosis
 - Rash

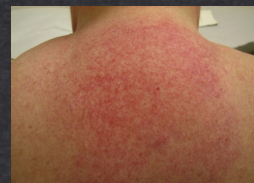
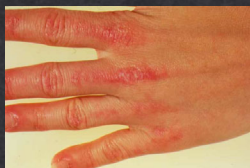
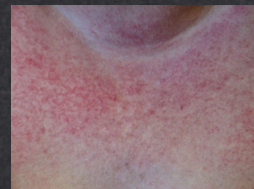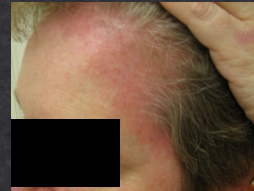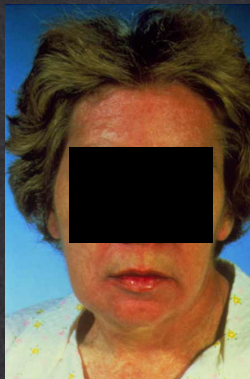“Good history and examination ..can not be replaced”

- Age at symptom onset
 - Birth vs. childhood vs. adulthood
 - Mild childhood sx. are usually missed
- Evolution of symptoms
 - Acute/sub-acute vs. Chronic
 - Static vs. Episodic
- PMH
 - Thyroid, parathyroid, adrenal, GH, cancer, HIV, DM, Kidney disease
 - Cardiac, pulmonary, musculoskeletal
- FH
 - X-linked, AD, AR, maternal transmission
- SH
 - Smoking >>paraneoplastic
- Meds
 - Statins, amiodarone, chloroquine, Colchicine, prednisone

Vignette

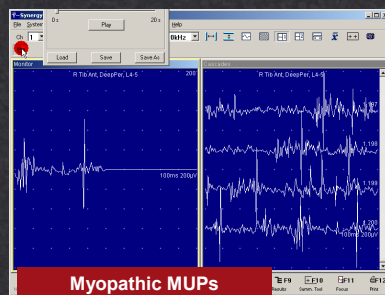
- 45 year old female
 - 2/12 h/o weakness
 - Difficulty going up steps
 - Facial and knuckles rash
 - Swelling around the eyes
 - Difficulty swallowing
 - Recent h/o ovarian cancer
 - CK normal



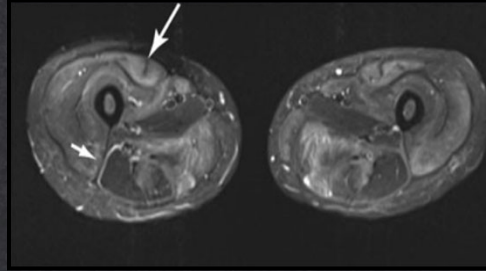
Dermatomyositis

Tests

- CK
 - High CK group (52-520 U/L)
 - Black men
 - Intermediate CK group (25-345 U/L)
 - Black women
 - Non-black men
 - Low CK group (25-145 U/L)
 - Non-black women
- CK in normal in 10% Dermatomyositis pts
- EMG



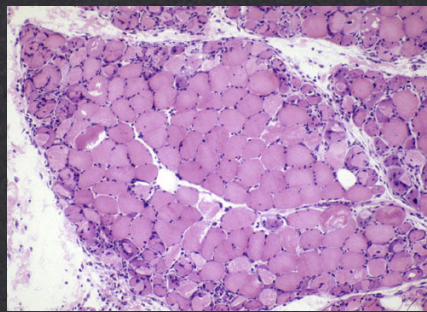
- Muscle MRI and US

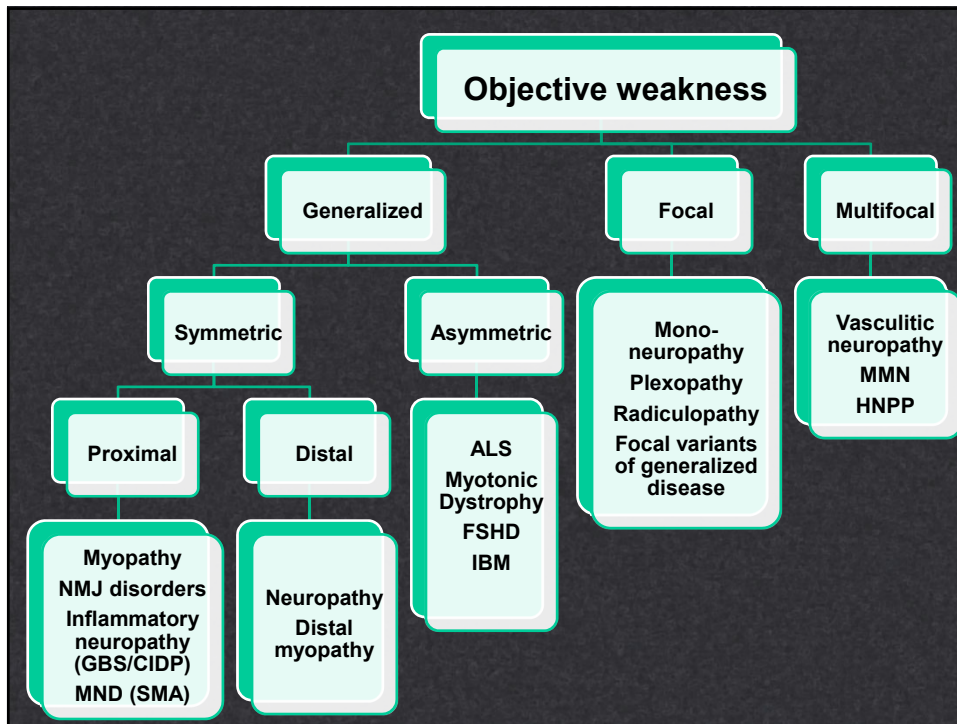


Mammen, A. L. (2010), Dermatomyositis and polymyositis. *Annals of the New York Academy of Sciences*, 1184: 134-153. doi:10.1111/j.1749-6632.2009.05119.x

Tests

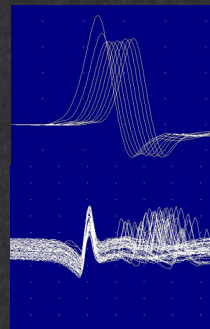
- ANA
- ESR
- TSH
- Auto-antibodies
 - Jo-1 20% IIM
 - Anti-SRP Myocarditis and NM
 - Mi-2 15-20% DM
 - HMGCOR
- Muscle biopsy
- Malignancy screen
 - Increased in dermatomyositis and NM
- Types of associated cancer
 - Breast, ovary, lung, pancreas, non-Hodgkin's, stomach, colorectal, melanoma
 - Nasopharyngeal (Asia)





Myasthenia Gravis

- Myasthenia Gravis
 - Fatigable weakness
 - Ocular symptoms
 - Bulbar
 - Facial muscle weakness
 - Dysphagia
 - Difficulty chewing
 - Painless
- Diagnosis
 - Serology
 - AchR (Binding antibodies)
 - Musk
 - LRP4
 - Pharmacological test
 - Edrophonium test
 - Ice Pack test
 - Electrodiagnostic tests
 - RNS
 - SFEMG
 - Radiology
 - CT chest (Thymoma)



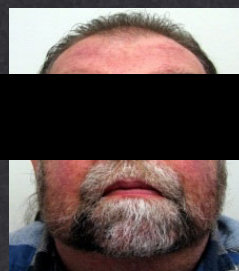
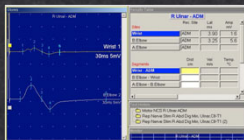
Lambert Eaton Myasthenic Syndrome (LEMS)

Classic features

- Weakness of proximal limb muscles
 - Chronic fluctuating
 - Some improvement in power with brief exercise
 - Patients report myalgia and muscle stiffness
- Autonomic symptoms
 - Dry mouth, erectile dysfunction, constipation
 - Orthostatic intolerance, urination difficulty, dry eyes
- Absent or hypoactive reflexes on examination
 - Post exercise facilitation

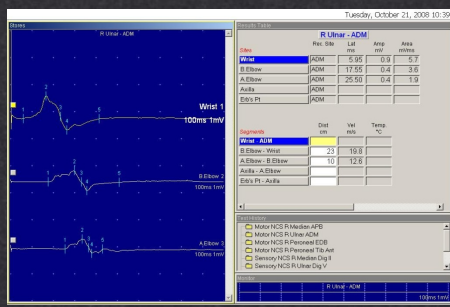
Diagnosis -serology

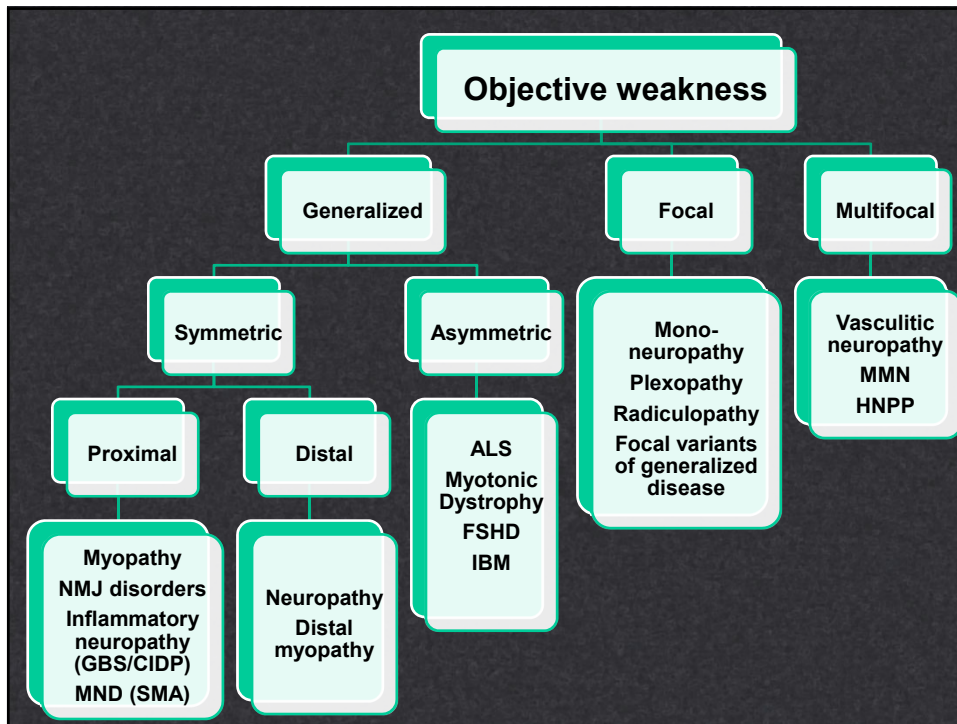
- P/Q Ca⁺⁺ antibodies
- Ct Chest (Paraneoplastic disorder (2/3))
 - 90% small cell lung cancer
- EDX



Chronic Inflammatory Demyelinating Polyradiculoneuropathy (CIDP)

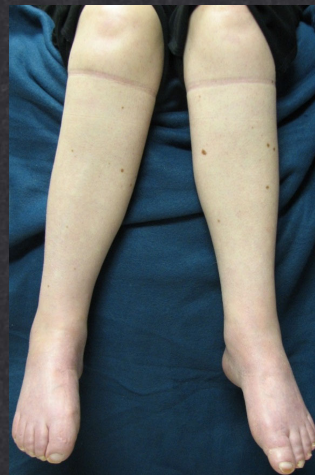- 38 year old AA female
- PMH: Hodgkin's lymphoma 1996 s/p MOPP/ABVD in remission
- **Two months history of**
 - Fatigue; tiredness
 - Numbness and tingling (feet-> legs to the thigh)
 - Progressive weakness (Non-ambulatory)
- Diagnosed with GBS and received IVIG treatment with improvement
- Recurrence after one month
 - Improved after second course of IVIG
- Examination
 - P>D weakness; Arms=Legs
- DTR absent
 - Distal sensory gradient
 - Pinprick & vibration
- Elevated CSF protein (>45mg/dl) 80-95%
- Cell count: Normal
 - 10% have > 5 lymph/mm³
 - AAN criteria: < 10 lymph/mm³
 - Increased cell count
 - HIV, Lyme, lymphoma, leukemia, Sarcoid
- IgM, IgG, IgA monoclonal gammopathy in about 25%





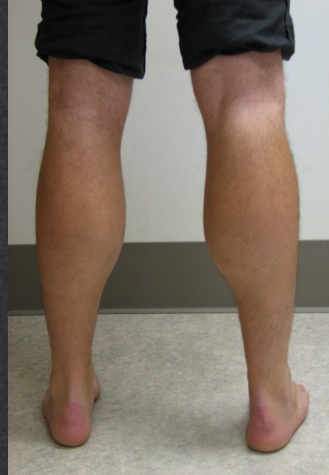Symmetric Distal Weakness Pattern

- Sensory examination – abnormal
 - Peripheral neuropathy
- Sensory examination –normal
 - Distal myopathy
 - Motor neuropathies
- It is not usual for diabetic neuropathy to cause weakness or bilateral foot drop

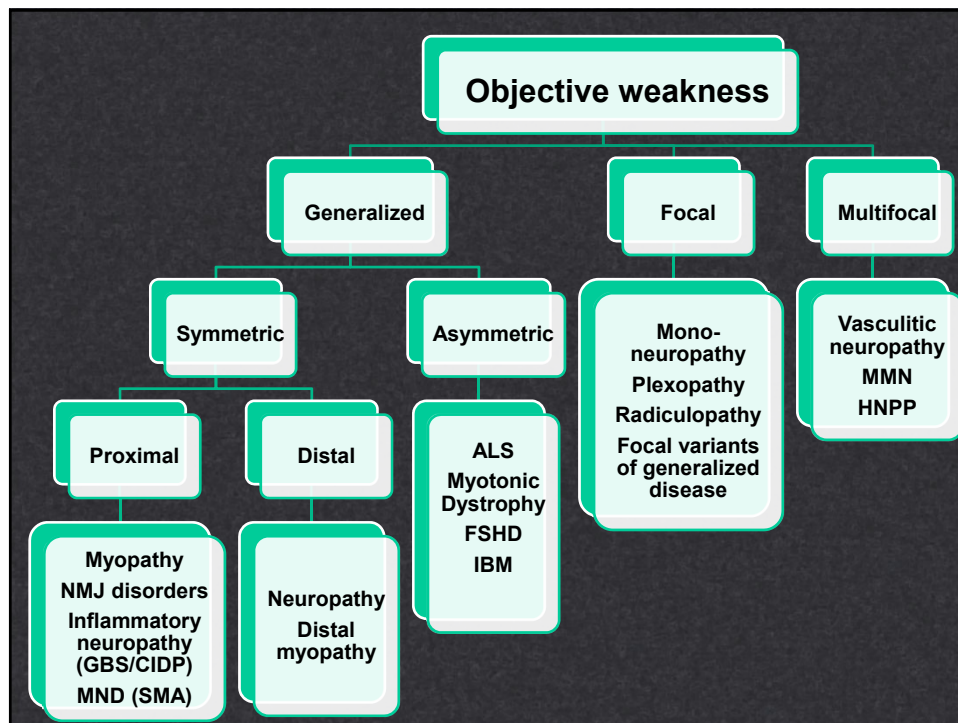


Vignette

- 23 year old man
 - Difficulty running and toe walking since age 3
 - No arm weakness or sensory symptoms
 - FH: Pos. with male to male transmission
 - Weak ankle dorsiflexor and big toe extensor
 - CK normal
 - EMG myopathic

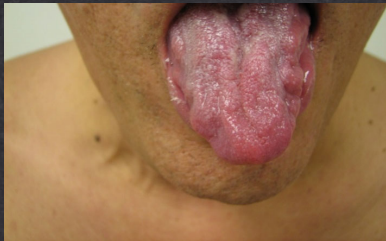
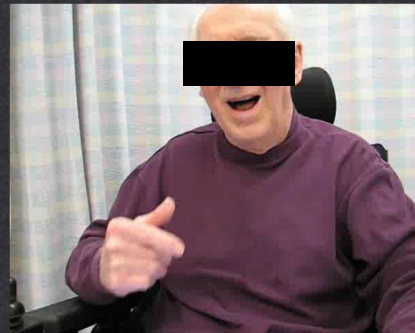
Distal myopathies



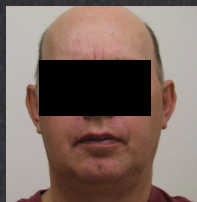
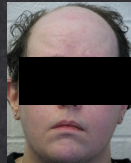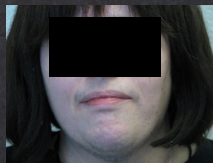
Amyotrophic Lateral Sclerosis-ALS

- ALS
 - UMN plus LMN
- Weakness
- Muscle atrophy
- Cramps
- Fasciculation's
- Dysphagia
- Dysarthria
- Pseudobulbar affect



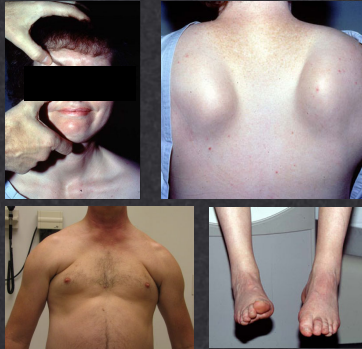Myotonic Dystrophy 1 (DM1)

- 42 year old female
- Stiffness of the hands x 5 years
- Swallowing difficulty
- Cataract surgery age 20
- Pacemaker
- Excess daytime sleepiness
- Most common adult muscular dystrophy
- AD inheritance
- Single locus in chromosome 19q13.3
- dystrophin myotonia protein kinase (*DMPK*)
- 3' untranslated region with increase in trinucleotide CTG repeats
- Multisystem disease
 - Cardiac conduction defectsPacemaker
 - Cardiomyopathy
 - Hypersomnia
 - Cognitive Impairment
 - Gastrointestinal symptoms
 - Insulin insensitivity



FSHD

- 32 y/o female
- Facial weakness
- Sleep eyes open
- Can't whistle
- Difficulty raising arm above shoulder
- Shoulder pain
- Pos. FH
- Autosomal dominant linked to 4q35
- Deletion of 3.3 kb repeated sequence (D4Z4)
- Symptoms begin < age 20 in ~ 80%
- *Typically* begins in face; subtle or absent ~4%
- Shoulder weakness, pain presenting c/o in 80%
- ~20% asymptomatic at dx
- 15% will require use of wheel chair

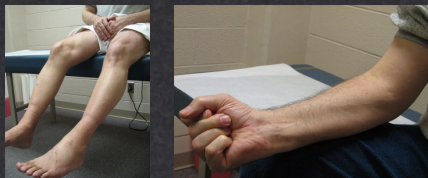
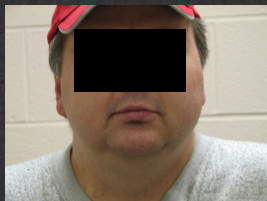
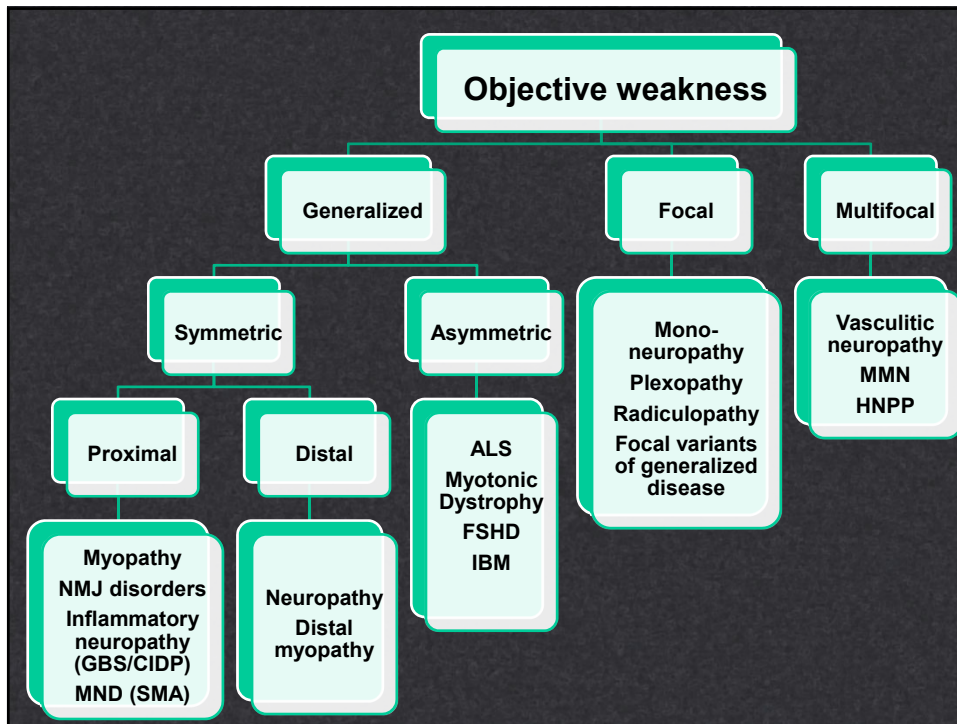
Mimics

- LGMD (Calpain)
- Acid maltase deficiency
- Myofibrillar myopathy
- Scapulo-peroneal dystrophy

Sporadic Inclusion Body Myositis (sIBM)

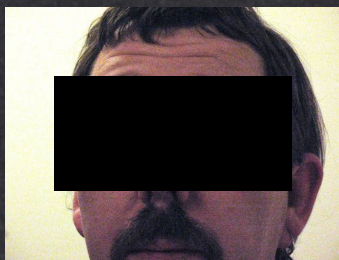
- 52 year old male
- 3 years history of grip weakness and walking difficulty
- Recently trouble swallowing
- Examination
 - Asymmetric wrist and finger flexor weakness
 - Bilateral quad (Knee extensor) weakness
- Facial weakness -mild
- Commonest inflammatory myopathy after age 50
- Refractory PM
 - = IBM or Dystrophy
- More common in men
- Onset: Months-Years
- Dysphagia ~30-60%
- CK mild to moderate elevation
- Not responsive to immunosuppressive Rx



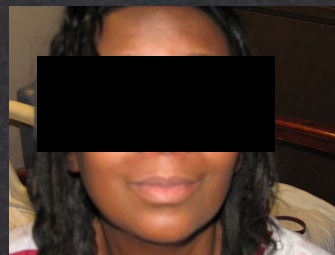

Ptosis With or Without Ophthalmoplegia Pattern

- 35 year old
- Droopy eyelids
- Progressive ophthalmoplegia
- Proximal weakness
- Short stature
- Third degree AV block
- Ptosis alone
 - Myotonic dystrophy
 - Cong. Myopathy
 - Myofibrillar Myopathies
- Ptosis and Ophthalmoplegia
 - OPMD
 - Mitochondrial myopathy
 - Ex. CPEO
 - NMJ disorders Ex. MG

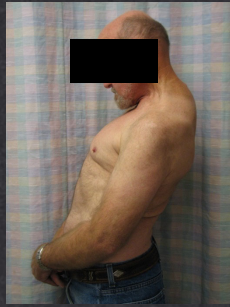

Kearns-Sayre Syndrome



Neck Extensor Weakness

- Dropped head syndrome
- DD: ALS, MG, Parkinson's
- Examples
 - INEM
 - Inflammatory myopathy
 - FSHD
 - MD
 - Congenital Myopathy

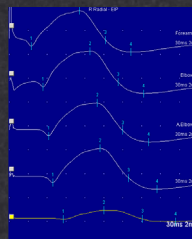


INEM

- 7th decade or older
- Weakness over days to Wks.
- Dull or burning neck pain
- Some report deltoid weakness
- EMG changes limited to cervical (mid to lower) and upper thoracic spine
- MRI fatty replacement and atrophy of the paraspinal muscles.

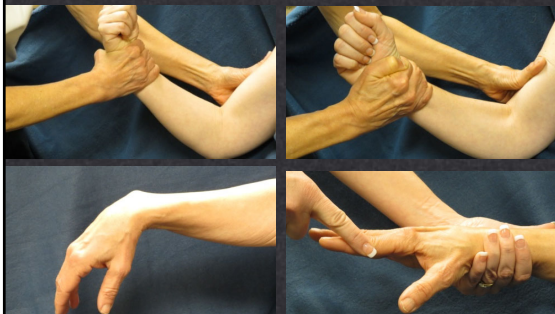Focal versus multifocal lesion Missing the forest for the trees!

- 20 year old college student
- One week history of wrist drop
- No sensory symptoms
- No trauma
- Examination
 - Wrist and finger extension weakness
 - Elbow flexion weakness
 - No sensory deficit



Hereditary neuropathy with liability to pressure palsies (HNPP)

- Autosomal dominant
- PMP22 gene deletion
- Recurrent and multiple focal neuropathies
 - Trivial compression
- Commonly involved nerves
 - Peroneal; radial; ulnar; median



- Is it vasculitic neuropathy?
- Is it diabetic lumbosacral radiculopathy?
- Is it neuralgic amyotrophy?

Take Home Message

- Detailed history and exam are fundamental steps to reaching a specific diagnosis
- Pattern of weakness and presence or absence of sensory changes help guide the diagnosis
- Normal CK does not exclude muscle disease
- High CK is not necessary indicative of muscle disease
- EMG is a valuable diagnostic tool for weakness